



## Case Report

## Nasopharyngeal airway aspiration: An uncommon cause of sudden respiratory distress in hospitalized patients

Kosar Hussain <sup>a</sup>, Sara Hussain <sup>b,\*</sup>, Jawed Abubaker <sup>c</sup>, Raees Ahmed <sup>d</sup><sup>a</sup> General Medicine, Goulburn Valley Health, Victoria, Australia<sup>b</sup> Intern, Rashid Hospital, Dubai Health Authority, Dubai, United Arab Emirates<sup>c</sup> Ziauddin Medical University, Karachi, Pakistan<sup>d</sup> Diagnostic Group, Beaumont, TX, USA

## ARTICLE INFO

## Article history:

Received 13 February 2018

Received in revised form

28 March 2018

Accepted 29 March 2018

Available online 17 April 2018

## Keywords:

Nasopharyngeal airway

Aspiration

Respiratory distress

X-ray

## ABSTRACT

An elderly, bed ridden patient with a history of stroke was admitted for management of aspiration pneumonia. Two days after insertion of a nasopharyngeal airway, sudden respiratory distress prompted further investigations which led to the eventual diagnosis and removal of the nasopharyngeal airway that had been aspirated. The device was removed under conscious sedation with fiber optic bronchoscopy.

Copyright © 2018 The Emergency Medicine Association of Turkey. Production and hosting by Elsevier B.V. on behalf of the Owner. This is an open access article under the CC BY-NC-ND license (<http://creativecommons.org/licenses/by-nc-nd/4.0/>).

## 1. Introduction

Nasopharyngeal airway (NPA) is one of the simplest adjuncts used to maintain the patency of the upper airway and for pulmonary toilet. Nevertheless, its use is not completely devoid of complications.<sup>1</sup> One of the rarer complications is the displacement of the NPA into the distal parts of the airway.<sup>2–4</sup> This displacement of airway devices is more likely to occur in patients with diminished airway reflexes secondary to a neurological impairment. It may present classically as acute respiratory distress in a high-risk patient.<sup>4</sup> Thus, a brief history and clinical examination may give rise to a clinical suspicion, but the final diagnosis may be secured via radiological imaging modalities to locate the source of the sudden respiratory distress. Comparison to previous imaging is recommended to rule out other pathologies that may be concomitant with the NPA aspiration. The occurrence of this complication can be reduced by selecting an appropriately sized nasopharyngeal airway device, using NPA with fixed flange and by securing it in position to avoid dislodgement.

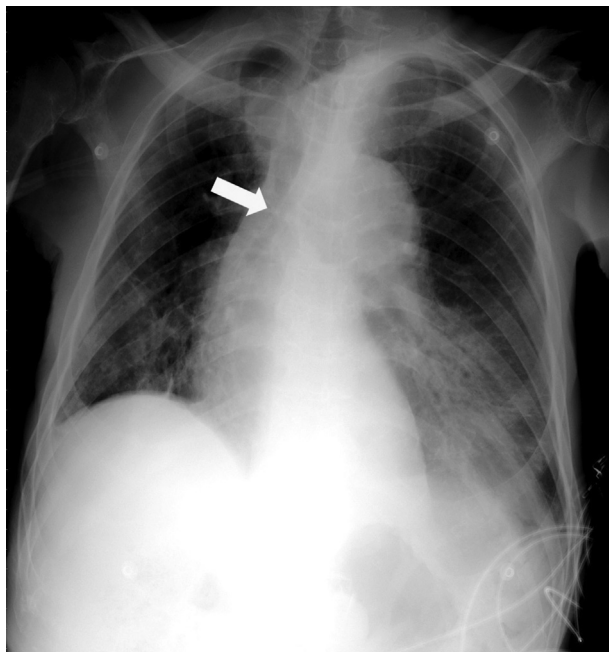
## 2. Case presentation

An elderly bed-ridden patient with history of stroke and GCS of 12/15 was admitted with aspiration pneumonia. He was noted to have a weak cough reflex and copious secretions. When he was initially assessed in the ED, his airway was secured with a size 6.5 NPA to facilitate suctioning. The appropriate size was selected by measurement of the distance from the tip of the patient's nose to the earlobe. A lubricant was used to facilitate its passage through the nose. The flange was loosely secured with tape to the cheeks. The relevant care pathway was initiated to manage the diagnosis and the patient was admitted to the medical ward. After 48 hours the patient suddenly developed signs of respiratory distress with worsening hypoxemia. His oxygen saturation level, which was initially stable at 94% in room air dropped to 80% and he required supplemental oxygen. ABG showed worsening respiratory acidosis. An urgent portable chest x-ray was obtained which displayed a foreign body in the trachea with extension into the right main bronchus (Fig. 1). No other relevant x-ray findings were appreciated in comparison to previous imaging that explained the sudden clinical deterioration. The clinical notes were retrospectively reviewed, and it was realized that the NPA was missing and most likely had dislodged into the bronchus due to the patient's poor gag reflex because of his previous stroke. Once diagnosed, the patient


\* Corresponding author.

E-mail address: [dr.sarahussain@hotmail.com](mailto:dr.sarahussain@hotmail.com) (S. Hussain).

Peer review under responsibility of The Emergency Medicine Association of Turkey.



**Fig. 1.** Chest x-ray showing dislodgment of the nasopharyngeal airway into the lower trachea with extension into the right main bronchus. Yellow arrow points at the nasopharyngeal airway.



**Fig. 2.** Nasopharyngeal airway with an internal diameter of 6.5 mm.

was transferred to the ICU where fiber optic bronchoscopy was done under conscious sedation. The device was visualized at the carina extending into the right main bronchus. Biopsy forceps was passed through the working channel to hold and retrieve the foreign body. Once the device had been pulled up to the vocal cords, it was retrieved using a Magill's forceps and the airway was cleared (see Fig. 2). The patient made a complete recovery and was discharged home in a few days' time.

### 3. Discussion

NPA devices are commonly-used respiratory adjuncts that are used in clinical practice for a variety of indications. However, they carry the potential risk of becoming aspirated in patients with impaired cough reflex. Complications that may occur in case of NPA aspiration can range from minor soft tissue injury up to severe life-threatening airway obstruction. These complications can be considered significant when addressing patient safety, both individually and cumulatively. We highlight the importance of training medical staff to properly secure the NPA device after their placement to prevent their dislodgement. Also, these devices should be removed as soon as the patient's condition improves, and their use is no longer required. Various 'barriers' such as safety pins and tapes can be attached to the flange to prevent its distal migration.<sup>5–7</sup> In the event of aspiration, however, the NPA may be removed using either rigid or flexible bronchoscopy.<sup>8,9</sup> While rigid bronchoscopy remains the modality of choice for removal of impacted foreign bodies in the airway, flexible bronchoscopy is increasingly getting recognition as the initial method of intervention in selected cases.<sup>9,10</sup> Keeping in mind, there is always the possibility of conversion to rigid bronchoscopy in case of difficulty in retrieving the foreign body or encountering other complications.

### Financial disclosure

No financial relationships relevant to this article to disclose.

### Conflict of interest

None declared.

### Contributors

All authors have participated equally in article preparation and final review of the manuscript.

### References

1. Roberts K, Whalley H, Bleetman A. The nasopharyngeal airway: dispelling myths and establishing the facts. *Emerg Med J.* 2005 Jun 1;22(6):394–396.
2. Brun CA, Mihm F. Where did it go? aspiration of a nasopharyngeal airway. *Chest.* 2008 Oct 1;134(4):30C.
3. Milam MG, Miller KS. Aspiration of an artificial nasopharyngeal airway. *Chest.* 1988 Jan;93(1):223–224.
4. Dua K, Saxena KN, Dua CK. Airway within airway: a case report. *Indian J Anaesth.* 2004;48:486–487.
5. Bajaj Y, Gadepalli C, Knight LC. Securing a nasopharyngeal airway. *J Laryngol Otol.* 2008 Jul;122(7):733–734. Epub 2007 Nov 26.
6. Grube P, Fan D, Pothula V, Vonfrolio C, Tsang D, Hoffman D. Prevention of aspiration of nasopharyngeal airway. *Indian J Anaesth.* 2010 Jan 1;54(1):74.
7. Mahajan R, Kumar S, Gupta R. Prevention of aspiration of nasopharyngeal airway. *Anesth Analg.* 2007 May 1;104(5):1313.
8. Limper AH, Prakash UB. Tracheobronchial foreign bodies in adults. *Ann Intern Med.* 1990 Apr 15;112(8):604–609.
9. Rodrigues AJ, Oliveira EQ, Scordamaglio PR, Gregório MG, Jacomelli M, Figueiredo VR. Flexible bronchoscopy as the first-choice method of removing foreign bodies from the airways of adults. *J Bras Pneumol.* 2012 May-Jun;38(3):315–320.
10. Jamshed N, Madan K, Ekka M, Guleria R. Successful flexible bronchoscopic management of a large-sized aspirated partial denture. *BMJ Case Rep.* 2014 Mar 20, 2014:bcr2013202371.