

Contents lists available at [ScienceDirect](http://www.elsevier.com/locate/TJEM)

Turkish Journal of Emergency Medicine

journal homepage: <http://www.elsevier.com/locate/TJEM>

A young puerperal woman presenting to emergency department with severe dyspnea

Adnan Yamanoglu ^{a,*}, Nalan Gokce Celebi Yamanoglu ^b, Sumeyye Cakmak ^a, Ozgur Sogut ^a^a Haseki Education and Research Hospital, Department of Emergency Medicine, Istanbul, Turkey^b Beykoz State Hospital, Department of Emergency Medicine, Istanbul, Turkey

ARTICLE INFO

Article history:

Received 12 May 2017

Accepted 3 July 2017

Available online 6 July 2017

Keywords:

Acute heart failure

Echocardiography

Cardiomyopathy

Ultrasound

ABSTRACT

Peripartum cardiomyopathy (PPCM) is an idiopathic cardiomyopathy presenting with heart failure (HF) secondary to left ventricular systolic dysfunction towards the end of pregnancy or in the months following delivery, where no other cause of HF is found. The symptoms and signs of this rare disorder mimic those of the physiological changes of pregnancy or other cardiovascular diseases. Consequently, its diagnosis is frequently delayed, which worsens an already poor prognosis. Here, we report a young adult who was diagnosed with PPCM, early, with the help of focused cardiac ultrasonography, performed after presenting to the emergency department with nonspecific respiratory complaints, including dyspnea and hemoptysis, which suggested at first pulmonary embolism.

Copyright © 2017 The Emergency Medicine Association of Turkey. Production and hosting by Elsevier B.V. on behalf of the Owner. This is an open access article under the CC BY-NC-ND license (<http://creativecommons.org/licenses/by-nc-nd/4.0/>).

1. Introduction

Dyspnea, fatigue, cough, and ankle edema are common during pregnancy and the puerperium. These complaints may be signs of fatal disorders, but may also develop secondary to the physiological changes of pregnancy.¹ Therefore, such symptoms encountered in pregnancy and puerperium may be attributed to physiological changes associated with pregnancy, and the underlying fatal disorders may be missed. Peripartum cardiomyopathy (PPCM) is one of these fatal disorders; it is a rare cause of heart failure (HF) in women of reproductive age. PPCM is an idiopathic cardiomyopathy presenting with HF secondary to left ventricular (LV) systolic dysfunction towards the end of pregnancy or in the months following delivery, where no other cause of HF is found. The LV may not be dilated but the ejection fraction (EF) is nearly always reduced below 45%.² Although its exact cause is unknown, multiparity, black race, advanced age at pregnancy, gestational hypertension, and preeclampsia are considered risk factors.³ Its incidence varies among countries, with incidences of 1: 2289–4000 reported for the United States,⁴ 1:1299 for Haiti,⁵ and 1:1000 for South Africa.⁶ Despite its low incidence, the disorder has a high mortality rate

of 28–30%, even with appropriate therapy.^{7,8}

Here, we report a young adult who was diagnosed with PPCM, early, with the help of focused cardiac ultrasonography (FoCUS), performed after presenting to the emergency department (ED) with nonspecific respiratory complaints, including dyspnea and hemoptysis, which suggested at first pulmonary embolism.

The aim of this report was to improve the likelihood of an earlier diagnosis in the course of the PPCM, which is infrequently reported from emergency departments, with the help of the increasingly widespread use of sonography in the ED.

2. Case presentation

A 25-year-old woman gave birth to her first child by elective caesarean section at 40 weeks. She presented to the ED 3 days later with dyspnea and hemoptysis. She had a history of asthma, but no other cardiac or non-cardiac disorders. Except for nausea and vomiting between the sixth-tenth weeks of pregnancy and dyspnea, ankle edema in the last month, she had had no other difficulties during her pregnancy. These symptoms were considered to be physiological changes of pregnancy by her primary obstetrician. She had no external disease and was not using any medication on a regular basis. The arterial blood pressure values of the patient during the pregnancy and after birth were normal.

The patient's initial vital signs were blood pressure 125/83 mmHg, heart rate 140 beats/min, respiratory rate 20 breaths/

* Corresponding author.

E-mail address: adnanyaman29@gmail.com (A. Yamanoglu).

Peer review under responsibility of The Emergency Medicine Association of Turkey.

min, temperature 36.1 °C, and oxygen saturation 95% on 3–4 L/min by oxygen mask.

On physical examination she was tachycardiac, and a 1/6 systolic murmur was present best at the apex of heart. Rales were heard at the basal and middle zones of both lungs at end-inspiration and bilateral rhonchi during expiration. Mild pitting edema (1+) was noted over both ankles and the pretibial region. No difference was found in the diameters of both legs, nor was there any calf tenderness.

Electrocardiography on admission showed sinus tachycardia at 140 beats per minute and negative T waves in V₁ and V₂. The initial differential diagnosis for her unstable condition included pulmonary embolism, acute heart failure, and pneumonia. At the bedside, the emergency physician performed combined lung, cardiac and three-point compression ultrasonography (for deep vein thrombosis) to obtain a rapid diagnosis of the patient's condition. This revealed bilateral multiple ultrasonographic B-lines interspaced by less than 3 mm, which were considered signs of alveolar edema⁹ (Fig. 1a). Cardiac ultrasonography showed left ventricular global hypokinesia and dilatation, a visually assessed left ventricular systolic function (LVSF) of moderate to severe heart failure, a prominent pericardial effusion around the right atrium with no signs of tamponade (Fig. 1b–c). Additionally, right heart chambers were not dilated and no signs of right heart failure were evident. Both lower extremity deep veins were evaluated as compressible at three points.

With these findings, intravenous (IV) loop diuretic (furosemide), IV nitrate (gliserol trinitrat) and IV digoxin were administered to patient immediately. Plasma B-type natriuretic peptide (NT-proBNP), D-dimer, cardiac troponin I (cTnI) and chest x-ray were obtained for differential diagnosis. Comprehensive echocardiography from a cardiologist, vascular doppler ultrasound from a radiologist was requested.

A chest x-ray taken after partial stabilization of the patient showed cardiomegaly and increased reticular densities in the lower and middle zones bilaterally (Fig. 2). Comprehensive echocardiography performed by cardiologist showed that the LVEF with biplane simpson's method was 35% and that the left ventricular diameter was 65 mm and mild-moderate mitral regurgitation. There was no evidence of right heart failure. There was no pathologic sign of deep vein thrombosis at vascular ultrasound performed by the attending radiologist. The troponin value was within normal limits, the D-dimer was 570 ng/mL (0–500 ng/mL), and the plasma NT-proBNP level was 1070 pg/mL (>125 pg/mL). The high level of D-dimer was attributed to the fact that the patient had recently had a childbirth. There was no additional finding that supported the pulmonary embolism at echocardiography and vascular ultrasound.

Subsequently, she was transferred to the cardiac intensive care unit and were received supplemental oxygen, noninvasive ventilation, IV antibiotherapy (seftriaxone), IV loop diuretic (furosemide), IV digoxin, low dose IV nitroglycerin, IV inotropic therapy (dobutamine). Her blood and sputum cultures did not reveal any

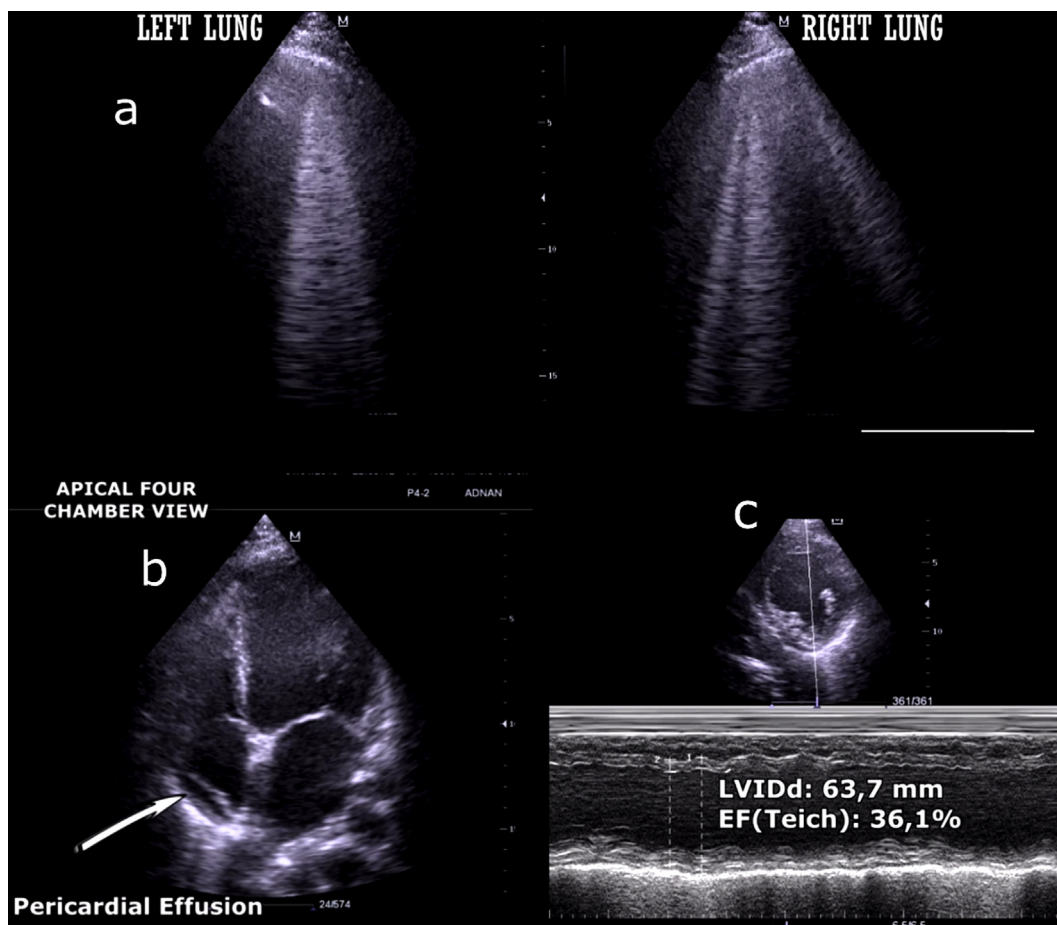


Fig. 1. Lung and cardiac ultrasound. Figure 1a: Lung ultrasound showed multiple ultrasonographic B-lines both right and left middle lung zones. Figure 1b: Apical 4-chamber view showed dilated left ventricle and pericardial effusion around right atrium. Figure 1c: Evaluation of left ventricular systolic function via M-Mode at the parasternal short axis. The ejection fraction measured by the Teichholz method indicates left ventricular systolic dysfunction and left ventricular dilatation.

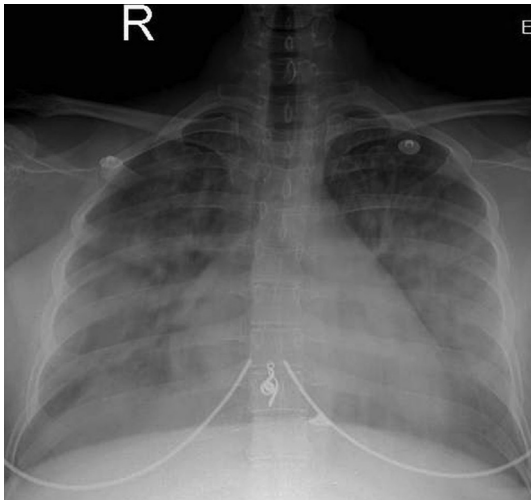


Fig. 2. Chest X-ray showed cardiomegaly and increased reticular densities in the lower and middle zones bilaterally.

growth and was stopped IV antibiotherapy. On the tenth day of admission, her comprehensive echocardiography with biplane Simpson's method revealed an EF of 48% (first day cardiologist and emergency medicine specialist were agreed on LVEF = 35%). Her medical therapy was tailored and she was discharged uneventfully.

3. Discussion

Although its exact cause is unknown, PPCM is thought to result from increased cardiac stress due to the increased blood volume during gestation, oxidative stress, increased proinflammatory cytokines, cleavage of prolactin to an angiostatic N-terminal 16 kDa prolactin fragment, abnormal serum relaxin levels, cardiotropic viruses, underlying myocarditis and impaired vascular endothelial growth factor signaling because of upregulated soluble fms-like tyrosine kinase.^{2,10} Signs of myocarditis were detected in 50% of cases undergoing endomyocardial biopsy.¹¹ There was no growth in two blood cultures obtained from our patient; however, no viral gene study or endomyocardial biopsy was done, since a good response to therapy was obtained.

The risk factors for PPCM include multiparity and higher gestational age.¹² However, 25%–75% of cases occur in young women giving birth to their first child.¹³ Our patient was 25 year old and this was her first pregnancy.

PPCM usually presents with dyspnea, fatigability, palpitations, and edema.⁴ However, 60–70% of pregnant women experience dyspnea during pregnancy.¹⁴ These symptoms also suggest other disorders, such as lower respiratory infection and pulmonary embolism. The risk of venous pulmonary embolism increases by 4- to 5-fold in pregnancy compared with healthy persons.¹⁵ Therefore, dyspnea accompanied by hemoptysis may make clinicians primarily consider pulmonary embolism. Our patient also had dyspnea and hemoptysis as major symptoms. Patients with PPCM may also develop pink frothy sputum or expectorate frank blood in the sputum depending on the severity of the pulmonary edema. And the patients may complain of one of these two findings.

FoCUS may play a critical role in differentiating or excluding these conditions. Echocardiographic criteria according to the 2010 ESC Working Group; LVEF nearly always less than 45%. The left ventricle may or may not be dilated.² Our patient had no history of any cardiac or non-cardiac condition that might cause HF. As assessed by an ED physician, her LVFS was moderate to severe heart

failure, LVIDd 3.50 cm/m², and LVFS 17%. Early use of FoCUS accelerated the management of this patient and probably reduced mortality and morbidity. But the limitations of the use FoCUS in the hands of physicians who are inexperienced should be acknowledged. FoCUS has been increasingly recognized as a tool to help clinicians evaluate and expedite management in patients with potentially life threatening conditions. There is a growing trend in the use of focused cardiac ultrasound in the emergency department without specific expertise. Only individuals sufficiently trained should use focus cardiac ultrasound to obtain information in the emergency setting. These individuals need to understand the information that is being obtained and to use it correctly. FoCUS should not replace the need for an echocardiogram performed and read by an expert in that field.

We expect that the incidence of PPCM, which is mostly diagnosed late in its course,¹ will increase currently with the increasing pregnancy age. Thanks to the widespread use of cardiac ultrasonography in emergency departments, PPCM can now be recognized and appropriately managed in a timely manner.

4. Conclusion

The symptoms and signs of this rare disorder mimic those of the physiological changes of pregnancy and other heart and lung diseases. Therefore, emergency physicians first responding to dyspneic women should consider this disorder and perform FoCUS, even when the symptoms and signs are compatible with the normal physiology of pregnancy. FoCUS in ED would lead to an earlier diagnosis and reduce its mortality.

References

1. Abboud J, Murad Y, Chen-Scarabelli C, et al. Peripartum cardiomyopathy: a comprehensive review. *Int J Cardiol.* 2007;118:295–303.
2. Sliwa K, Hilfiker-Kleiner D, Petrie MC, et al. Current state of knowledge on aetiology, diagnosis, management, and therapy of peripartum cardiomyopathy: a position statement from the Heart Failure Association of the European Society of Cardiology Working Group on peripartum cardiomyopathy. *Eur J Heart Fail.* 2010;12:767.
3. Mann DL, Zipes D, Libby P, et al. *Braunwald's Heart Disease: A Textbook of Cardiovascular Medicine.* tenth ed. Philadelphia, PA: Saunders; 2014.
4. Mielniczuk LM, Williams K, Davis DR, et al. Frequency of peripartum cardiomyopathy. *Am J Cardiol.* 2006;97:1765–1768.
5. Fett JD, Christie LG, Carraway RD, et al. Five-year prospective study of the incidence and prognosis of peripartum cardiomyopathy at a single institution. *Mayo Clin Proc.* 2005;80:1602–1606.
6. Desai D, Moodley J, Naidoo D. Peripartum cardiomyopathy: experiences at king edward VIII hospital, Durban, South Africa and a review of the literature. *Trop Doct.* 1995;25:118–123.
7. Sliwa K, Förster O, Tibazarwa K, et al. Long-term outcome of Peripartum cardiomyopathy in a population with high seropositivity for human immunodeficiency virus. *Int J Cardiol.* 2011 Mar 3;147(2):202–208.
8. Duran N, Gunes H, Duran I, et al. Predictors of prognosis in patients with peripartum cardiomyopathy. *Int J Gynaecol Obstet.* 2008;101:137–140.
9. Bouhemad B, Zhang M, Lu Q, et al. Clinical review: bedside lung ultrasound in critical care practice. *Crit Care.* 2007;11:205.
10. Patten IS, Rana S, Shahul S, et al. Cardiac angiogenic imbalance leads to peripartum cardiomyopathy. *Nature.* 2012;485:333.
11. Felker GM, Jaeger CJ, Klodas E, et al. Myocarditis and long-term survival in peripartum cardiomyopathy. *Am Heart J.* 2000;140:785–791.
12. Modi KA, Illum S, Jariatul K, et al. Poor outcome of indigent patients with peripartum cardiomyopathy in the United States. *Am J Obstet Gynecol.* 2009;201:171. e1–5.
13. Sliwa K, Förster O, Libhaber E, et al. Peripartum cardiomyopathy: inflammatory markers as predictors of outcome in 100 prospectively studied patients. *Eur Heart J.* 2006;27:441–446.
14. Simon PM, Schwartzstein RM, Weiss JW, Fencel V, Tegtsoonian M, Weinberger SE. Distinguishable types of dyspnea in patients with shortness of breath. *Am Rev Respir Dis.* 1990;142:1009–1014.
15. Heit JA, Kobbervig CE, James AH, Melton 3rd LJ, et al. Trends in the incidence of venous thromboembolism during pregnancy or postpartum: a 30-year population-based study. *Ann Intern Med.* 2005;143:697–706.