

Contents lists available at [ScienceDirect](http://www.elsevier.com/locate/TJEM)

Turkish Journal of Emergency Medicine

journal homepage: <http://www.elsevier.com/locate/TJEM>

Original Article

Accuracy of point-of-care ultrasound using low frequency curvilinear transducer in the diagnosis of shoulder dislocation and confirmation of appropriate reduction



Javad Seyedhosseini ^a, Jaleh Saiidian ^a, Amirpejman Hashemi Taheri ^b, Elnaz Vahidi ^{a,*}

^a Tehran University of Medical Sciences, Shariati Hospital, Emergency Medicine Research Center, Iran

^b Tehran University of Medical Sciences, Shariati Hospital, Radiology Department, Iran

ARTICLE INFO

Article history:

Received 8 March 2017

Received in revised form

28 June 2017

Accepted 4 July 2017

Available online 9 July 2017

Keywords:

Shoulder dislocation

Reduction

Ultrasound

Radiography

ABSTRACT

Background: Ultrasound (US) is an effective modality in the evaluation of shoulder dislocation and reduction. In most studies, high frequency US probes have been used.

Objective: To determine the sensitivity and specificity of low frequency US in the diagnosis of shoulder dislocation and its proper reduction in the emergency department (ED).

Methods: In a prospective observational study 84 patients, suspicious of shoulder dislocation, were enrolled in our study. In ED, they all underwent low frequency (curve) probe US examination by the emergency physician at the time of admission. Standard radiographies of their shoulder joints were taken later and then reported by the attending radiologist. As soon as the shoulder dislocation was confirmed, reduction of the joint was done under procedural sedation and analgesia. US and radiography of the relocated joint were taken for the second time. The sensitivity and specificity of low frequency US were compared with radiography by the appropriate statistical analysis.

Results: In comparison to radiography, US had a sensitivity of 100.0%, specificity of 80.0%, positive predictive value of 98.7%, and negative predictive value of 100.0% in diagnosis of shoulder dislocation. The specificity of US in diagnosis of proper reduction of the joint, was estimated to be 98.7% with a negative predictive value of 100.0%. US took a significantly less time than radiography to be performed ($p < 0.001$).

Conclusions: Low frequency US is highly accurate in diagnosing shoulder dislocation and its proper reduction. Thus it might be a good substitute for radiography in these situations.

Copyright © 2017 The Emergency Medicine Association of Turkey. Production and hosting by Elsevier B.V. on behalf of the Owner. This is an open access article under the CC BY-NC-ND license (<http://creativecommons.org/licenses/by-nc-nd/4.0/>).

1. Introduction

The glenohumeral joint is the most commonly dislocate major joint in the body. Most shoulder dislocations are anterior.^{1,2} The incidence of shoulder dislocation is estimated to be 17 per 100000 annually and two distinct age and gender peaks have been reported to be affected the most, first in men 20–30 years of age and the second in older women.³

Shoulder dislocation is a true emergency. In most emergency departments (EDs), its diagnosis is initially confirmed by radiography. In almost all cases pre-reduction X-rays are necessary. Ultrasound (US) can save time in this procedure, because it is ready and accessible. US does not have the risk of exposing to radiation induced by other imaging modalities.

Physicians usually require X-rays of the joint before and after the reduction.⁴ There are some reasons behind this order: dislocation confirmation, concomitant fracture diagnosis, appropriate reduction and finding new fractures after reduction.⁵ Recent evidence about taking radiography of the dislocated shoulder joint seems controversial.^{5–8} Some of these studies have recommended that physicians could omit unnecessary pre and post-reduction X-rays, which cause extra expense, radiation and prolong ED stay.⁹

Most previous studies have used high frequency linear probe in shoulder US. In this study, we decided to use low frequency US in

* Corresponding author. Dept. Emergency Medicine, Tehran University of Medical Sciences, Emergency Medicine Research Center, Shariati Hospital, Tehran, Iran.

E-mail addresses: jshosseini@tums.ac.ir (J. Seyedhosseini), saiidian2013@gmail.com (J. Saiidian), apecmanht@yahoo.com (A. Hashemi Taheri), evahidi62@yahoo.com (E. Vahidi).

Peer review under responsibility of The Emergency Medicine Association of Turkey.

the diagnosis of shoulder dislocation and its proper reduction. Low frequency US probe seems to be especially more helpful in shoulder dislocation and in muscular patients. If US has a good sensitivity and specificity comparing to radiography, we could substitute this rapid and easy modality with X-rays.

2. Materials and methods

2.1. Participants and study design

This was a prospective observational and diagnostic accuracy study. All patients with the history and clinical suspicion of shoulder dislocation, who were admitted to the EDs of 2 university hospitals, were enrolled in our study. This study was performed during one year, from April 2014 to April 2015. The study was approved by the ethics committee of university. All patients were required to read informed consent letter and signed it if they accepted to participate in our study.

Our inclusion criteria were: patients older than 16 years old, with clinical suspicion of shoulder dislocation of any kind, induced by any reason (trauma or spontaneously), who were admitted to the EDs of two tertiary referral hospitals. The exclusion criteria were: pregnant patients, patients with depressed level of consciousness or ones who needed emergent surgical operation like laparotomy.

Patients who met the inclusion criteria, underwent US

examination by an emergency medicine (EM) faculty or a chief resident who passed a 6-h training course of US examination in shoulder dislocation by the chief investigator (EM attending physician). They passed a 2-month-pilot course on real patients in order to gain enough experience and skill in normal and abnormal shoulder US.

We used the low frequency (curve) US probe (Sonosite M-Turbo, C 3–5 MHz probe) and put it horizontally on the posterior rim of shoulder joint with its marker pointing towards patient's lateral. The method we used for joint US and the results are shown in Fig. 1.

Whatever the US result, all patients underwent an X-ray of their joint before reduction. This pre-reduction standard radiography helped the responsible physician to diagnose joint dislocation and detect any associated fractures. The results of X-rays were reported by the attending of radiology with delay. EM faculties and chief residents were blinded to the X-ray results.

After that the dislocation was confirmed, PSA was done and reduction of the joint was attempted. Both the US and radiography were repeated after the reduction.

2.2. Primary and secondary outcomes

Our primary outcome was determining the diagnostic accuracy of US using low frequency transducer in diagnosing shoulder. Our secondary outcome was comparison of the time spent in the 2 techniques.

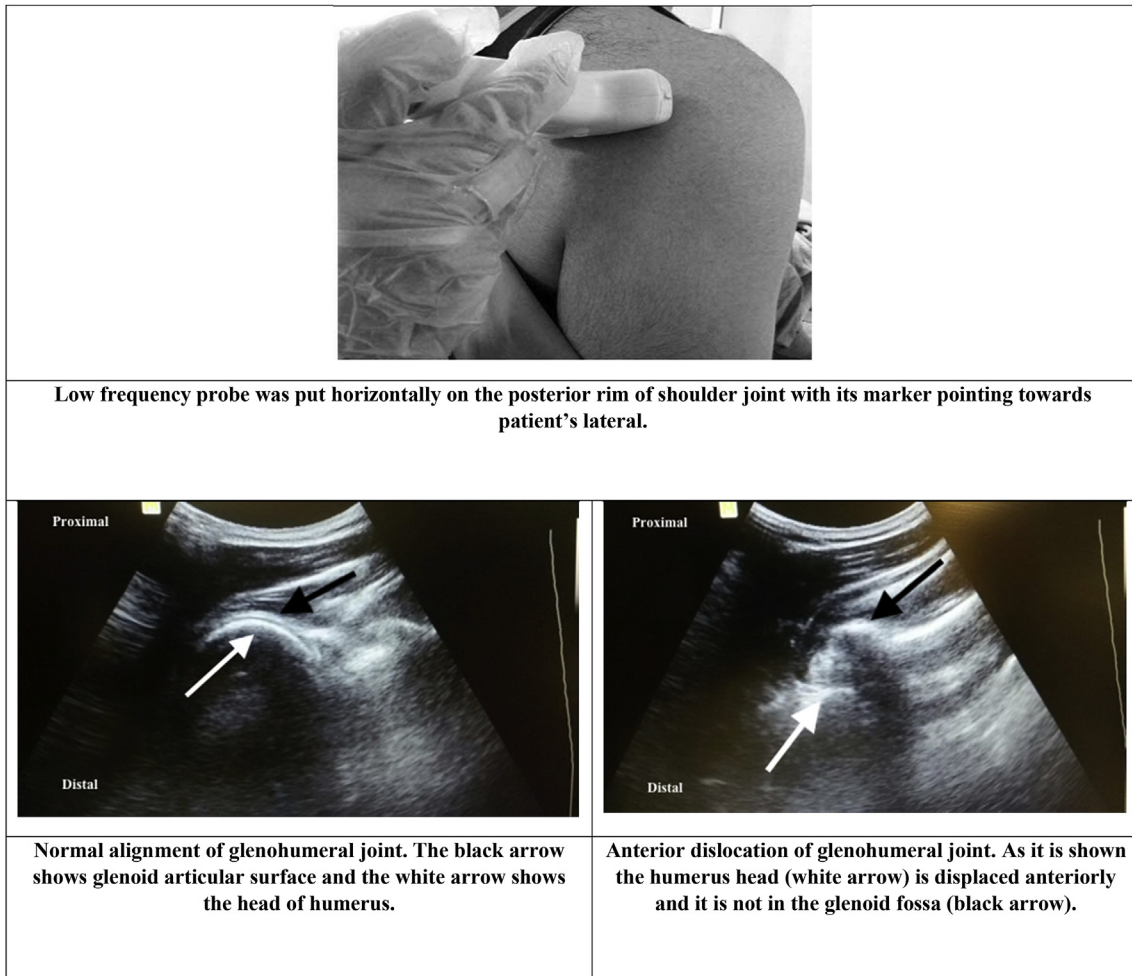


Fig. 1. Shoulder joint ultrasound exam.

Table 1
Comparison of ultrasound versus radiography.

		Ultrasound	Radiology
Dislocation before reduction	Yes	80	79
(Total number of patients: 84)	No	4	5
Fracture before reduction	Yes	1	1
(Total number of patients: 84)	No	83	83
Persistent dislocation after reduction	Yes	1	0
(Total number of patients: 79)	No	78	79
New fracture after reduction	Yes	0	0
(Total number of patients: 79)	No	79	79

2.3. Statistical analysis and sample size calculation

We enrolled all the patients with shoulder dislocation who met our inclusion criteria and were admitted to the EDs of the two tertiary referral hospitals mentioned, during one year. In order to have a sensitivity of 90% with the accuracy rate of 7%, we needed 80 patients to be enrolled in our study (considering 90% prevalence of shoulder dislocation in this population).

The data are presented as mean values or proportions, and differences in these values are presented with accompanying 95% confidence intervals (95% CIs). Variables were tested for normality (Kolmogorov–Smirnov test) before analysis. Analytical statistical tests included the unpaired, two-tailed *t*-test for continuous normally distributed data and the Mann–Whitney *U* test for non-normal and ordinal data. The chi-square and Fisher's exact tests were used to compare proportions of the qualitative variables. Diagnostic factors of US and radiography were analyzed by Cross tabulation and their sensitivity and specificity were calculated. The level of significance was 0.05. SPSS for Windows software (version 22) was used for all data analysis.

3. Results

During a year 84 patients were enrolled in our study. None of them had the exclusion criteria. Finally, 79 patients had shoulder dislocation and all of them were anterior. The mean \pm SD age of patients was 35.9 \pm 15.7 years old and 70 patients (83.3%) were male. The mechanisms of shoulder dislocation were direct trauma (29.7%), falling (34.5%), motor vehicle collision (5.9%) and spontaneous dislocation (29.7%).

Most of the dislocated joints were reduced with the traction-countertraction method (54 cases 68.7%). The rest were reduced by other methods; scapula manipulation in 7 cases (8.7%), Stimson technique in 4 cases (5%) and external rotation in 14 cases (17.6%).

First US examination (before reduction) detected anterior shoulder dislocation in 80 patients (95.2%). US found associated fractures in only one case (1.2%). The mean time from admission to the 1st US examination was 7.19 \pm 4.54 min. One of the cases whom

US was compatible with anterior shoulder dislocation, had no pathology in radiography (this was falsely positive in US).

First radiography detected shoulder dislocation in 79 patients (94%) and all of them was anterior type. Radiography found associated fractures in only one case (1.2%). The mean time from admission to taking the 1st radiography was 20.80 \pm 8.83 min.

The mean time from admission to the 1st US examination was significantly less than the time to taking radiography ($p < 0.001$).

Second US examination (after reduction) confirmed proper shoulder reduction in 78 out of 79 patients (98.7%). New fractures were not found in any cases after reduction. US reported reduction failure in one case which was not compatible with the radiography result. The mean time from shoulder reduction to the 2nd US examination was 4.4 \pm 2.5 min.

Second radiography (after reduction) confirmed proper shoulder reduction in all 79 patients (100%). New fractures were not found in any cases after reduction. None of the cases needed repeated attempt for reduction. The mean time from shoulder reduction to taking the 2nd radiography was 18.3 \pm 8.3 min.

The mean time from reduction to the 2nd US examination was significantly less than the time to taking radiography ($p < 0.001$).

Table 1 shows these results in detail.

Table 2 shows the value of US in our study.

4. Discussion

Our study showed that low frequency US could be a good modality in the diagnosis of shoulder dislocation and associated fractures both in pre-reduction and post-reduction situations. The study declared that US might be an acceptable substitute for radiography because of its high accuracy in these conditions. The greater significance may be time savings and allowing for results to be obtained prior to sedation wearing off.

US possesses multiple significant advantages over radiography. First, this modality is cheap, portable and accessible in detection of shoulder dislocation. Second, it does not have the radiation exposure seen in X-rays. Third, it is a safe method in situations where X-rays are forbidden like in pregnancy or some active cancers. Fourth, as it is shown in our study, US has the superiority of time saving in contrast to radiography.

Reviewing literature, we found that most similar studies used curvilinear probe. US appeared to have different sensitivity and specificity in these studies.

Ahmadi et al., in 2016 compared the 2 modalities in diagnosis of proper shoulder reduction. They found that US detected persistent dislocation of the shoulder joint by a sensitivity of 53.8% and a specificity of 100%. They showed that US might be inadequate for this evaluation.¹⁰

Akyol et al., in 2016 evaluated 103 patients with suspicion of shoulder dislocation. They reported that US had a good sensitivity

Table 2
Validity of ultrasound in detection of shoulder dislocation and accompanying fractures both before and after shoulder reduction.

Value	Sensitivity	Specificity	Negative likelihood ratio	Positive likelihood ratio	Positive predictive value	Negative predictive value
Pre-reduction dislocation diagnosis	100.0% (95% CI ^a : 95.4–N/A ^b)	80.0% (95% CI: 28.3–99.4)	N/A	5.0 (95% ci: 0.8–28.8)	98.7% (95% CI: 93.2–99.9)	100.0% (95% CI: 39.7–N/A)
Pre-reduction fracture diagnosis	100.0% (95% CI: 2.5–N/A)	100.0% (95% CI: 95.6–N/A)	N/A	N/A	100.0% (95% CI: 2.5–N/A)	100.0% (95% CI: 95.6–N/A)
Persistent dislocation after reduction	N/A	98.7% (95% CI: 93.1–99.9)	N/A	N/A	0.0% (95% CI: N/A–97.5)	100.0% (95% CI: 95.3–N/A)
Post-reduction new fracture diagnosis	N/A	100.0% (95% CI: 95.4–N/A)	N/A	N/A	N/A	100.0% (95% CI: 95.4–N/A)

^a Confidence interval (95% CI) is shown in parenthesis.

^b This calculation was not possible because of the small number of patients.

and specificity (100%–100% respectively) in diagnosis of shoulder dislocation. It also had an acceptable specificity (84.2%) in detection of associated fractures.¹¹

In a similar study in 2013, Abbasi et al., showed that US had 100% sensitivity in both the diagnosis of shoulder dislocation and the appropriate reduction.¹²

Simão et al., in 2012 evaluated 56 patients with chronic anterior instability of shoulder joint and they concluded that US had a sensitivity of 20–100% and a specificity of 80–100% in diagnosis of this problem. They also reported that MRI had a sensitivity of 80–100% and a specificity of 50–100% in comparison to US.¹³

4.1. Limitations of the study

One of our limitation was the small sample size. Further studies with larger sample sizes are needed to accurately determine US validity in the diagnosis of shoulder dislocation. All dislocations were anterior so the results could not be extended to posterior dislocations. There were very few overall fractures, which limited the ability to assess bedside ultrasound's ability to evaluate for this. Our sampling was convenience sample thus the other limitation included selection bias. Shoulder dislocation is also a clinical diagnosis. An experienced physician can diagnose a patient with shoulder dislocation without having an X-ray or ultrasonography. This problem can cause deterioration in blinding of operator and therefore the operator is always prone to bias.

5. Conclusion

This study revealed that low frequency US had an acceptable accuracy in the diagnosis of shoulder dislocation. It might be a good substitute for radiology in this purpose.

Statements

There are no submissions or previous reports that might be regarded as redundant publication of the same or very similar work.

There is no conflict of interest.

The manuscript has been read and approved by all the authors. The requirements for authorship as stated in this document have been met, and each author believes that the manuscript represents honest work.

Contributors

All authors made an individual contribution to the writing of the

article including: conception and design, acquisition of data or analysis and interpretation of data; drafting the article or revising it critically for important intellectual content; final approval of the version published.

Competing interests

None declared. Patient consent Obtained.

Funding

None.

References

- Riebel GD, McCabe JB. Anterior shoulder dislocation: a review of reduction techniques. *Am J Emerg Med.* 1991;9(2):180–188.
- May Jr VR. Posterior dislocation of the shoulder: habitual, traumatic, and obstetrical. *Orthop Clin North Am.* 1980;11(2):271–285.
- Chalidis B, Sachinis N, Dimitriou C, Papadopoulos P, Samoladas E, Pournaras J. Has the management of shoulder dislocation changed over time? *Int Orthop.* 2007;31(3):385–389.
- Joshi N, Lira A, Mehta N, Paladino L, Sinert R. Diagnostic accuracy of history, physical examination, and bedside ultrasound for diagnosis of extremity fractures in the emergency department: a systematic review. *Acad Emerg Med.* 2013;20(1):1–15.
- Yuen CK, Mok KL, Kan PG, Wong YT. Bedside ultrasound for verification of shoulder reduction with the lateral and anterior approaches. *Am J Emerg Med.* 2009;27(4):503–504.
- Kahn JH, Mehta SD. The role of post-reduction radiographs after shoulder dislocation. *J Emerg Med.* 2007;33(2):169–173.
- Shuster M, Abu-Laban RB, Boyd J, Gauthier C, Shepherd L, Turner C. Prospective evaluation of a guideline for the selective elimination of pre-reduction radiographs in clinically obvious anterior shoulder dislocation. *CJEM.* 2002;4:257–262.
- Beck S, Chilstrom M. Point-of-care ultrasound diagnosis and treatment of posterior shoulder dislocation. *Am J Emerg Med.* 2013;31(2).
- Kendall JL, Hoffenberg SR, Smith RS. History of emergency and critical care ultrasound: the evolution of a new imaging paradigm. *Crit Care Med.* 2007;35(5):S126–S130.
- Ahmadi K, Hashemian AM, Sineh-Sepehr K, Afzal-Aghaee M, Jafarpour S, Rahimi-Movaghar V. Bedside ultrasonography for verification of shoulder reduction: a long way to go. *Chin J Traumatol.* 2016;19(1):45–48.
- Akyol C, Gungor F, Akyol AJ, et al. Point-of-care ultrasonography for the management of shoulder dislocation in ED. *Am J Emerg Med.* 2016;34(5):866–870.
- Abbasi S, Molaie H, Hafezimoqhadam P, et al. Diagnostic accuracy of ultrasonographic examination in the management of shoulder dislocation in the emergency department. *Ann Emerg Med.* 2013;62(2):170–175.
- Simao MN, Nogueira-Barbosa MH, Muglia VF, Barbieri CH. Anterior shoulder instability: correlation between magnetic resonance arthrography, ultrasound arthrography and intraoperative findings. *Ultrasound Med Biol.* 2012;38(4):551–560.