

A Rare Case in the Emergency Department: Holmes-Adie Syndrome

Sahin COLAK, Mehmet Ozgur ERDOGAN, Ahmet SENEL, Ozge KIBICI,
Turker KARABOGA, Mustafa Ahmet AFACAN, Hızir Ufuk AKDEMİR

Department of Emergency Medicine, Haydarpaşa Numune Training and Research Hospital, Istanbul, Turkey

SUMMARY

Holmes-Adie syndrome (HAS) is a rare syndrome characterized by tonic pupil and the absence of deep tendon reflexes. HAS was first described in 1931 and is usually idiopathic, with incidences reported to be 4-7 per 100,000. Although tonic pupil is usually unilateral, it can also be bilateral. Enlarged and irregular pupil is usually noticed by the patient. Light reflex is weak or unresponsive. Another characteristic of HAS is the absence of deep tendon reflexes, and unilateral involvement is more common. This case report emphasizes that HAS should be considered in the differential diagnosis of patients presenting to the emergency department with anisocoria, and the dilute pilocarpine test can be used in diagnosis.

Key words: Emergency department; Holmes-Adie syndrome; pilocarpine.

Introduction

Holmes-Adie syndrome (HAS) is characterized by tonic pupil and the absence of deep tendon reflexes. The incidence is reported to be 4-7 per 100,000.^[1-4] Tonic pupil seen in HAS is usually unilateral, but it can rarely be seen in both eyes. The involvement of deep tendon reflexes is a characteristic of HAS. The Achilles tendon reflex is most commonly affected. This case report emphasizes that HAS should be considered in the differential diagnosis of patients presenting to the emergency department with anisocoria.

Case Report

A 31-year-old female patient presented to the emergency department upon noticing in the mirror at home that her left pupil was bigger than the right. There was no disease, chronic medication use, or trauma story in the case history. The case reported no decrease in her vision except for difficulty when reading. The examination revealed that she had anisocoria, and her left pupil was dilated and irregular. The left pupil was unresponsive to direct and indirect light stimuli (Figure 1a). Eye movements were normal. Miosis was

Submitted: February 20, 2014 **Accepted:** April 21, 2014 **Published online:** January 20, 2015

Correspondence: Dr. Şahin Çolak. Haydarpaşa Numune Eğitim ve Araştırma Hastanesi, Acil Tıp Kliniği, İstanbul, Turkey.

e-mail: drsahincolak@hotmail.com



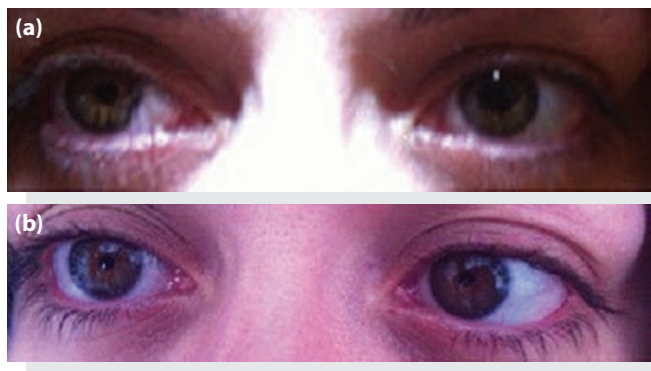


Figure 1. (a) The left pupil was unresponsive to direct and indirect light stimuli. (b) Pilocarpine was instilled into both eyes, 30 minutes later, anisocoria was now not observed.

present in both eyes at near vision. Motor and sensory examination was normal; however, bilateral Achilles reflex was absent. Other system examinations, vital signs, and laboratory values were normal. Visual field and macula of the case were evaluated as normal in consultation with the eye department. No pathology was detected in the cranial computed tomography (CT) and magnetic resonance imaging (MRI). The Neurology Department was consulted about the case. In order to confirm the diagnosis of suspected HAS, dilute pilocarpine 0.5% (Pilomin®) was instilled into both eyes. In the examination performed about 30 minutes later, anisocoria was now not observed (Figure 1b). Light reflexes were present in both eyes. The case was discharged after necessary information was provided.

Discussion

Anisocoria is defined as a difference of more than 0.1 mm in the diameter of the pupils. Many causes, from physiological anisocoria to HAS, can be included in the etiology of anisocoria.^[5-7]

Holmes-Adie Syndrome (HAS) is characterized by tonic pupil and the absence of deep tendon reflexes. It is usually idiopathic and more common in young women in the third decade of life.^[1-3] Our case was a 31-year-old woman. There was no known disease or chronic medication use in the case history. Cranial computed tomography (CT) and magnetic resonance imaging (MRI) was normal.

Tonic pupil as seen in HAS is usually unilateral, but can rarely be seen in both eyes. It occurs due to the injury of postganglionic parasympathetic nerve fibers. Diagnosis of unilateral involvement cases with no disease history is easier than those with bilateral involvement. The onset of tonic pupil is quite slow and usually noticed by the patient. The involved pupil is dilated and irregular compared to the other. Light reflex is weak or unresponsive. The near reaction in cases

with weak or unresponsive light reflex is defined as the light-near dissociation, which is generally present in HAS cases. Accommodation is also impaired.^[1,4,5] Our patient noticed that her pupils were unequal and presented to the emergency department. Her left pupil was affected and dilated and irregular compared to the other. Light reflex was unresponsive; however, contraction was present in both eyes at near vision. After the pilocarpine drop, light reflex and significant contraction was observed in the affected eye. There was no decrease in her vision, but she had difficulty in reading because of visual accommodation disturbances. These symptoms observed in our case corresponded to tonic pupil findings seen in HAS.

The involvement of deep tendon reflexes is a characteristic of HAS. The Achilles tendon reflex is most commonly affected. In general, unilateral involvement is common, but bilateral involvement has been also reported. The loss of tendon reflexes is permanent. Studies have proven that the number of nerve cells decreases in the thoracic and lumbar ganglia, and the myelin sheath is reduced by grey and white matter involvement in the posterior root and the medial region of the spinal cord. It is thus estimated that impaired spinal monosynaptic connections have a role in areflexia pathophysiology.^[1] Bilateral Achilles tendon reflexes were absent in the patient's neurological examination. Motor and sensory examination was normal. Our case was diagnosed with HAS based on normal neuroimaging, tonic pupil, and the absence of bilateral Achilles tendon reflex. Autonomic dysfunction may occur with HAS. It has been reported that HAS is accompanied by sweating, cardiovascular dysfunction, diarrhea, cough, and orthostatic hypotension.^[2,8-10] In our case, autonomic dysfunction was not observed.

Conclusion

HAS is one of the rare causes of anisocoria in the emergency department. In these cases, the pupil should be examined in detail. In case of tonic pupil and areflexia, emergency physicians should consider HAS in the differential diagnosis, and the diagnosis should be confirmed by pilocarpine test.

Conflict of Interest

The authors declare that there is no potential conflicts of interest.

References

1. Martinelli P. Holmes-Adie syndrome. *Lancet* 2000;18:356.
2. Guaraldi P, Mathias CJ. Progression of cardiovascular autonomic dysfunction in Holmes-Adie syndrome. *J Neurol Neurosurg Psychiatry* 2011;82:1046-9. [CrossRef](#)
3. Bremner FD, Smith SE. Bilateral tonic pupils: Holmes Adie

- syndrome or generalised neuropathy? *Br J Ophthalmol* 2007;91:1620-3. [CrossRef](#)
4. Bakkak B, Donmez H. Adie's tonic pupil. [Article in Turkish] *Turk Norol Derg* 2009;15:153-4.
 5. Turk A, Gunay M, Erdol H. The role of pupillometric measurements at different light amplitudes in diagnosis of Adie's tonic pupil. [Article in Turkish] *Genel Tip Derg* 2011;21:4.
 6. Wilhelm H, Wilhelm B. Diagnosis of pupillary disorders. In: Schiefer U, Wilhelm H, Hart W. *Clinical neuro-ophthalmology* 2007;55-69. [CrossRef](#)
 7. Bakkak B, Gedik S. Anisocoria. *TJO* 2012;42:68-72.
 8. Johnson RH, McLellan DL, Love DR. Orthostatic hypotension and the Holmes-Adie syndrome. A study of two patients with afferent baroreceptor block. *J Neurol Neurosurg Psychiatry* 1971;34:562-70. [CrossRef](#)
 9. Kimber J, Mitchell D, Mathias CJ. Chronic cough in the Holmes-Adie syndrome: association in five cases with autonomic dysfunction. *J Neurol Neurosurg Psychiatry* 1998;65:583-6. [CrossRef](#)
 10. Sogut O, Erdogan MO, Yigit M, Albayrak L. Anisocoria due to datura inoxia. *Emergency Med* 2013;3:162.