

Acute Coronary Syndrome Developed after Vincristine Administration

Vinkristin Tedavisi Sonrası Gelişen Akut Koroner Sendrom

Serkan ÖZTÜRK,¹ Davut BALTACI,² Selim AYHAN,¹ Mehmet YAZICI,¹ Ayhan SARITAŞ³

¹Department of Cardiology, Abant İzzet Baysal University, Faculty of Medicine, Bolu, Turkey;
²Departments of Family Medicine, ³Emergency Department, Duzce University Faculty of Medicine, Düzce, Turkey

SUMMARY

Vincristine and doxorubicin are among the most effective chemotherapeutic agents used in the treatment of malignancies in combination per protocols. However, these chemotherapeutic agents possess great risk for development of cardiotoxicity. The most common manifestations of cardiotoxicity due to use of those chemotherapeutic agents are arrhythmias, systolic dysfunction, cardiomyopathy, pericardial injury and myocardial ischemia. We present a case of acute coronary syndrome with complete atrio-ventricular (AV) block, developed after vincristine and doxorubicin chemotherapy in a patient with multiple myeloma and no cardiac history.

Key words: Atrio-ventricular block; doxorubicin; myocardial infarction; vincristine.

ÖZET

Vinkristin ve doksorubisin kombinasyonu kemoterapi protokollü olarak malignitelerin tedavisinde kullanılan en etkili kemoterapötik ajanlardandır. Ancak, bu kemoterapötik ajanlar kardiyotoksosite gelişimi için oldukça risklidir. Bu kemoterapötik ajanlar nedeniyle en sık görülen toksik yan etkiler, aritmiler, sistolik disfonksiyon, kardiyomiyopati, perikardiyal yaralanma ve miyokard iskemisidir. Burada, kardiyak açıdan risk faktörü olmayan multipl myelom tanısı ile vinkristin ve doksorubisin kemoterapisi aldıktan sonra akut koroner sendrom ve atriyoventriküler (AV) blok gelişen bir olguyu sunuyoruz.

Anahtar sözcükler: Atriyoventriküler blok; doksorubisin; miyokardiyal infarktüs; vinkristin.

Introduction

Vincristine and doxorubicin in combination are widely used as chemotherapeutic agents as part of the vincristine-adriamycin-dexamethasone (VAD) protocol. However, they have several side effects. Cardiac toxicity of vincristine and doxorubicin are affected by age, gender, pre-existing heart disease, hypertension and mediastinal irradiation.^[1] Cardiac toxicity may occur both in early and late stages after administration of vincristine.^[2] The most commonly seen manifestations are arrhythmias, myocardial dysfunction, pericardial injury and myocardial ischemia.^[1,3] Acute coronary syndrome has been reported as an uncommon, but serious, complication of treatment with vincristine.^[4,5]

Herein, we present a case of a patient, with no prior history of cardiovascular disease, who developed acute coronary syndrome and subsequently a complete atrioventricular (AV) block immediately after treatment with vincristine in combination of doxorubicin for multiple myeloma.

Case Report

The patient, a 60-year-old female, had been diagnosed with multiple myeloma 6 months prior to the current event. She was admitted to the hematology clinic of our hospital for 4th course of VAD protocol. The patient was evaluated for cardiac functions before starting chemotherapy. She had no cardiac risk factors (obesity, diabetes mellitus, hypertension,

Submitted (Geliş tarihi): July 26, 2011 **Accepted (Kabul tarihi):** November 01, 2011

Correspondence (İletişim): Serkan Öztürk, M.D. Abant İzzet Baysal Üniversitesi Tıp Fakültesi, Kardiyoloji Anabilim Dalı, Bolu, Turkey

e-mail (e-posta): drserkan69@hotmail.com

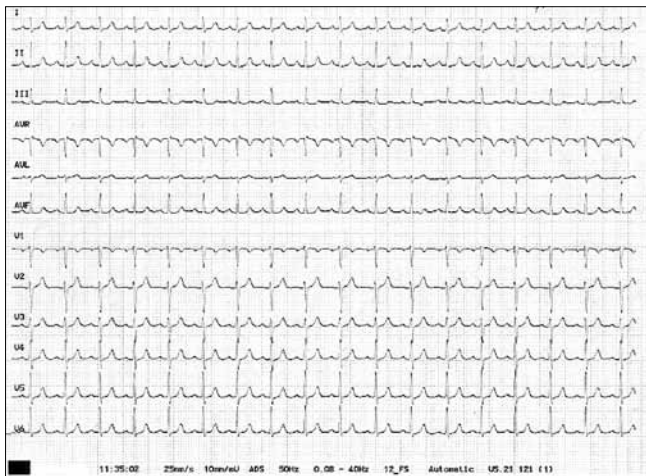


Figure 1. Electrocardiogram before chemotherapy.

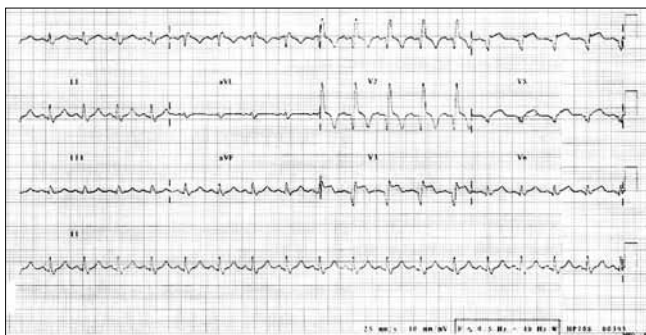


Figure 2. Electrocardiogram shows ST elevation and incomplete RBBB in emergency service.

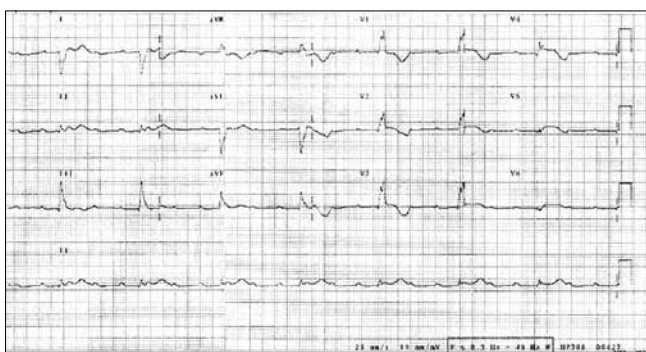


Figure 3. Electrocardiogram shows complete AV block in coronary care units.

cigarette smoking, family history) except age. On cardiac examination, she was physically normal. Electrocardiography showed sinus tachycardia with a heart rate of 103 beats per minute (bpm) (Figure 1). Echocardiography revealed normal cardiac dimensions and normal systolic function. On the basis of these findings, the patient was evaluated as fit to re-

ceive chemotherapy treatment. Following the 4th course of VAD chemotherapy protocol was given, she was discharged from the clinic.

The patient began to experience typical anginal chest pain in the second day of discharge. She was admitted to the emergency department on the 18th hour of beginning of chest pain. ST elevation in V1 through V6, incomplete right bundle branch block (RBBB), and sinus tachycardia were observed on ECG recording of the patient while in the emergency department (Figure 2). The patient was immediately diagnosed with acute anterior myocardial infarction, and was transferred to the coronary intensive care unit. Signs of complete AV block developed on ECG few hours after the admittance (Figure 3). A transient pacemaker was implanted to the patient due to hypotension. Cardiac markers obtained with the following results: troponin = 6.70 ng/ml, creatine kinase (CK) = 3061 U/L, creatine kinase muscle-brain type (CKMB) = 468 U/L and CKMB protein = 408 ng/ml. Hemo-gram and other biochemical markers of the patient were normal. The patient's rhythm improved after 1 week follow-up. Segmental wall motion disorder and apico-septal aneurysm consistent with anterior myocardial infarction was observed, and the ejection fraction was evaluated as 30% on echocardiography. There was no significant lesion on coronary angiography, except a plaque formation in the mid portion of the left anterior descending artery. The patient was discharged from the hospital on the 6th day of admission, with recommended treatment with ramipril 2.5 mg/d, metoprolol 50 mg/d, atorvastatin 40 mg/d, acetylsalicylic acid 100 mg/d. During the follow-up one month later, the patient underwent control echocardiography. Echocardiography revealed apico-septal aneurysm and improved left ventricular function (ejection fraction 50%).

Discussion

Vincristine and doxorubicin are widely used in the treatment of oncologic diseases, and they both possess cardiotoxic effects. It has been shown in the literature that vinca alkaloids, such as vincristine, cause endothelial damage and myocardial ischemia.^[6,7] It has also been demonstrated that cardiotoxic effects of doxorubicin are associated with excessive free radical formation and decrease in antioxidant radicals, sarkolemmal sodium-calcium exchange deterioration, and disruption of energy metabolism in myocardial cells.^[2,8] Doxorubicin has been responsible for cardiomyopathy, especially dilated cardiomyopathy, and its cardiotoxic affects are attenuated by vincristine. Combination of doxorubicin with vincristine is associated with a significant decrease in cytochrome C release, suggesting reduction of oxidative stress and inhibition of mitochondrial permeability transition.^[9]

Chest pain, T-wave inversions on ECG without rising of cardiac enzymes and symptoms of reversible cardiac ischemia as well as complicated myocardial infarction have been attributed to vinca alkaloids.^[6] Similarly, typical anginal chest pain and elevation of cardiac enzymes have occurred after vincristine is given in our case. In at least two cases of complete myocardial infarction, coronary angiography revealed normal epicardial vessels in the literature.^[10] Calvo-Romero et al.^[5] reported one patient who developed a Q-wave inferior and right ventricle myocardial infarction with post-infarction angina after receiving a third course of vincristine and doxorubicin for immunoglobulin A (IgA) multiple myeloma. Vincristine-doxorubicin combination was administered on fourth course of VAD protocol to our patient who suffered from IgA multiple myeloma. Ischemic heart disease may be serious but uncommon complication of treatment with several chemotherapeutic agents.

Herein, we presented a case with acute anterior myocardial infarction developed complete AV block after vincristine and doxorubicin therapy. It is likely that vincristine played a role in the development of anterior myocardial infarction in our patient, in the light of reports presenting similar cases in literature.

Conclusion

Vincristine is a cardiotoxic agent that it can cause ischemic heart disease. We suggest that vincristine should be used with great caution, even in patients with no preexisting cardiovascular risk factors, and physicians should be aware of this serious complication of chemotherapy.

References

1. Shan K, Lincoff AM, Young JB. Anthracycline-induced cardiotoxicity. *Ann Intern Med* 1996;125:47-58.
2. Steinberg JS, Cohen AJ, Wasserman AG, Cohen P, Ross AM. Acute arrhythmogenicity of doxorubicin administration. *Cancer* 1987;60:1213-8.
3. Jones RL, Swanton C, Ewer MS. Anthracycline cardiotoxicity. *Expert Opin Drug Saf* 2006;5:791-809.
4. Samuels BL, Vogelzang NJ, Kennedy BJ. Severe vascular toxicity associated with vinblastine, bleomycin, and cisplatin chemotherapy. *Cancer Chemother Pharmacol* 1987;19:253-6.
5. Calvo-Romero JM, Fernández-Soria-Pantoja R, Arrebola-García JD, Gil-Cubero M. Ischemic heart disease associated with vincristine and doxorubicin chemotherapy. *Ann Pharmacother* 2001;35:1403-5.
6. Cargill RI, Boyter AC, Lipworth BJ. Reversible myocardial ischaemia following vincristine containing chemotherapy. *Respir Med* 1994;88:709-10.
7. Mikaelian I, Buness A, de Vera-Mudry MC, Kanwal C, Coluccio D, Rasmussen E, et al. Primary endothelial damage is the mechanism of cardiotoxicity of tubulin-binding drugs. *Toxicol Sci* 2010;117:144-51.
8. Lenaz L, Page JA. Cardiotoxicity of adriamycin and related anthracyclines. *Cancer Treat Rev* 1976;3:111-20.
9. Chatterjee K, Zhang J, Tao R, Honbo N, Karliner JS. Vincristine attenuates doxorubicin cardiotoxicity. *Biochem Biophys Res Commun* 2008;373:555-60.
10. Allal J, Becq-Giraudon B, Pouget-Abadie JF, Sudre Y, Baraine R. 2 new cases of myocardial infarction after injection of vincristine. [Article in French] *Ann Cardiol Angeiol (Paris)* 1984;33:469-70.